

HISTOPATHOLOGICAL STUDY OF NON NEOPLASTIC AND NEOPLASTIC LESION OF SALIVARY GLAND IN BIKANER REGION

Qadir Fatima¹, Suman Kapuriya¹, Mukesh Kumar², L.A. Gauri²

¹Senior Professor in Department of Pathology, drliyakatgauri@gmail.com

¹Resident in Pathology Department, sumanrulaniya008@gmail.com

²Resident in Medical Oncology unit G.C.R.I. Ahmedabad, mukeshrulaniya008@gmail.com

²Senior Professor in Department of Medicine, drliyakatgauri@gmail.com

Correspondence Address: Dr. Mukesh Rulaniya, Room No. 72, Old P.G. Hostel, P.B.M. Campus, Bikaner (Rajasthan) 334001.

ABSTRACT

Aim: The purpose of this study was to assess the histopathological diversity of salivary gland lesion. (Including Non neoplastic and neoplastic lesions.) This is a prospective study conducted in PBM hospital and associated group of hospitals in Bikaner Zone.

Material & Methods: Total 80 cases was included in this study.

Results: Out of 80 cases, 32 cases were non neoplastic, 48 cases were neoplastic. In neoplastic lesion 40 cases were benign, 8 cases were malignant. In Bikaner zone benign neoplasm was predominant than malignant neoplasm. Non neoplastic lesion most commonly involve submandibular gland. Neoplastic lesion most commonly involve parotid gland. Most common benign tumor was pleomorphic adenoma and most common malignant tumor was mucoepidermoid carcinoma.

Conclusion: Timely diagnosis according to histology of salivary gland lesions decreases morbidity and mortality. And appropriate treatment according to nature of lesion whether it was non neo-plastic or non neoplastic. In neoplastic whether it was benign or malignant. In benign lesion surgical resection was only treatment, in malignant lesion after surgical resection chemotherapy or radiotherapy was given, and follow up of cases.

Key Words: Neoplastic, Non Neoplastic, Mucoepidermoid, Submandibular

INTRODUCTION

Salivary gland tissue is distributed widely. Salivary glands are two type, major & minor. The Major Salivary glands are the parotid, Sub-maxillary and sublingual glands.

- Minor salivary glands are found in the lips (More in the upper than lower), gingiva, floor of the mouth cheek, hard & soft palates, tongue, tonsillar areas, & oropharynx.
- Over 50% of salivary glands tumors are benign & approximately 70% to 80% of all salivary glands neoplasm originate in the parotid gland. The palate is the most common site of minor salivary glands tumors. The frequency of malignant lesions varies by the site. Approximately 20 to 25% parotid tumors, 35% to 40% of sub-mandibular tumors, 50% of palate tumors & over 90% of sublingual gland tumors are malignant. Histologically, salivary glands tumors represent the most heterogeneous group of tumors of any tissue in the body. Although there are almost 40 histological types of epithelial tumors of salivary glands. Some are exceedingly rare & may be subject of only few case reports. The most common benign major & minor salivary gland tumor is pleomorphic adenoma which comprises of half of the salivary gland tumors & 65% of

parotid gland tumors. The most common malignant major & minor salivary gland tumor is mucoepidermoid carcinoma which comprises of about 10% of all salivary gland neoplasm & approximately 35% of malignant salivary neoplasm. This neoplasm occurs most often in the parotid gland.

- Salivary gland neoplasm are remarkable for their histological diversity. These neoplasm include benign & malignant tumors of epithelial, mesenchymal & lymphoid origin. Salivary gland tumors pose a particular challenge to the surgical pathologist because of complexity of classification & the rarity of several entities, which may posses broad spectrum of morphological diversity in individual lesions. Thus it is difficult to differentiate between benign & malignant lesions.
- Histological grading of salivary gland tumor is important in determining the proper treatment approach. Clinical stage particular size may be the critical factor in determining the outcome of salivary gland malignancy & is more important than histological grade. In children & adolescent, 80% tumor are benign ie. pleomorphic adenoma & most common malignant tumor is mucoepidermoid carcinoma. Malignant lesions usually seen above the age of 60 years while benign lesions are usually above age of 40 years.

AIMS AND OBJECTIVE

1. To study the histopathological findings in various neoplastic and non-neoplastic lesions of salivary glands in Bikaner region.
2. To assess various types of salivary gland neoplastic and non-neoplastic lesions with regard to frequency, age and sex distribution.

MATERIAL AND METHODS

The present study was a prospective type of study. 80 cases of salivary gland lesions include. Biopsies and whole specimen was received in 10% formalin. A gross feature of the specimens received was recorded. Representative sections taken and after processing tissue was embedded in paraffin wax to make blocks after making section in microtome staining was carried out with Haematoxylin and eosin (H&E) stain.

Biopsies and whole specimen was received in 10% formalin. Gross features of the specimens received were recorded. Representative sections taken and after processing tissue was embedded in paraffin wax to make blocks after making section in microtome staining was carried out with Haematoxylin and eosin (H&E) stain and classifeied them according to WHO classification.

Whenever histological diagnosis become difficult nearly by H&E staining, especial stain was pressed upon the service to clear the dilemma. The special stain use were PAS, PAS with diastase, Alcian blue.

PAS (Periodic Acid Schiff) was done for staining mucin, PAS / AB(PeriodicAcid Schiff/ Alcian Blue) at pH 2.5 for nature of mucin i.e. neutral and acidic.

INCLUSION CRITERIA

All the neoplastic and non neoplastic lesions of the salivary gland were be included in the study.

EXCLUSION CRITERIA

- Lesions other than lesions of the salivary gland
- Autolysed/necrosed tissue specimen.

Inadequate biopsy

RESULTS**Table 1****Shows percentage of various tumours according to WHO Classification (n=80)**

Lesions	No.	Percentage
A. Non-Neoplastic Lesion	32	40.0
1. CNSS	27	38.8
2. Lymphoepithelial Cyst	1	1.3
3. Mucous Cyst	2	2.5
4. TB	2	2.5
B. Neoplastic Tumours	48	60.0
1. Benign	40	50.0
a. Basal cell adenoma.	1	1.3
b. Oncocytoma	1	1.3
c. Pleomorphic salivary adenoma.	32	40.0
d. Sebaceous Lymphadenoma	1	1.3
e. Warthin Tumour	5	6.3
2. Malignant	8	10.0
a. Adenocystic Carcinoma	2	2.5
b. Adenocarcinoma	2	2.5
c. Mucoepidermoid Ca	3	3.8
d. Carcinoma Ex Pleomorphic Adenoma	1	1.3
Total	80	100

Table 2**Distribution of cases according to site in relation to Histologic Type**

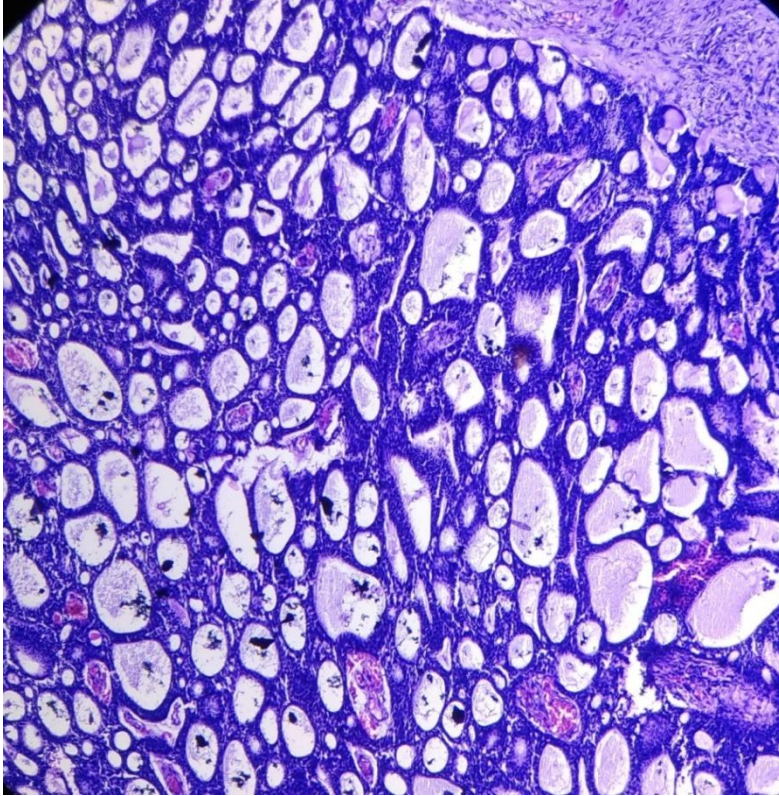
Site	Histologic Type						Total	
	Benign		Malignant		Non Neoplastic		No.	%
	No.	%	No.	%	No.	%		
Parotid	24	60.0	2	25.0	2	6.3	28	35.0
Submandibular	6	15.0	0	-	23	71.9	29	36.3
Minor	0	-	0	-	3	9.4	3	3.8
Sublingual	10	25.0	6	75.0	4	12.5	20	25.0
Total	40	100	8	100	32	100	80	100

Table 3**Benign salivary gland tumor according to histological type with reference to average age, sex and site distribution**

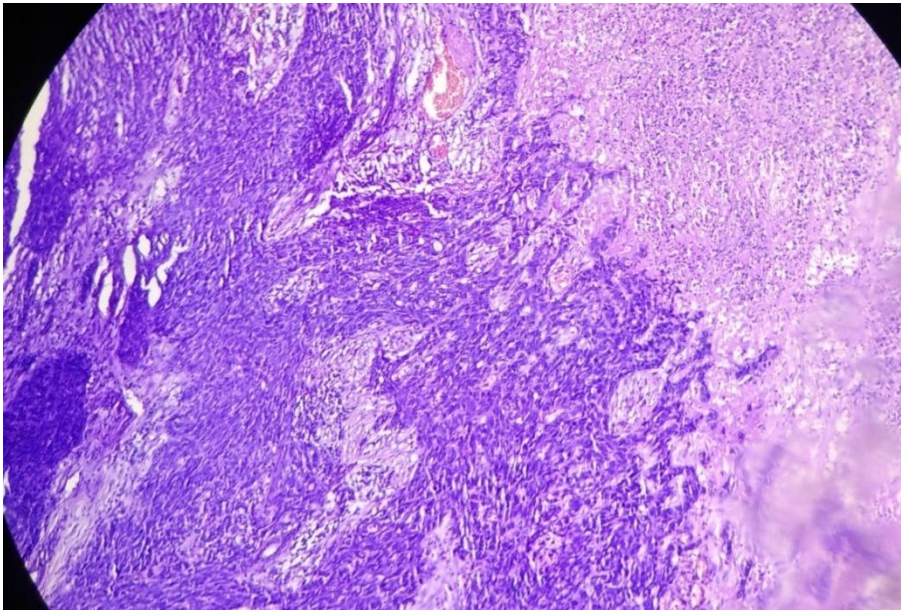
Type of Tumour	Total Cases	Average Age	Sex		Site			
			Female	Male	Parotid	Sub Mandibular	Sub Lingual	Minor
Neoplastic	48	37.87±14.63	15	33	26	6	16	0
Non Neoplastic	32	37.34±18.05	10	22	2	23	4	3

Table 4**Malignant salivary gland tumor according to histological type with reference to average age, sex and site distribution**

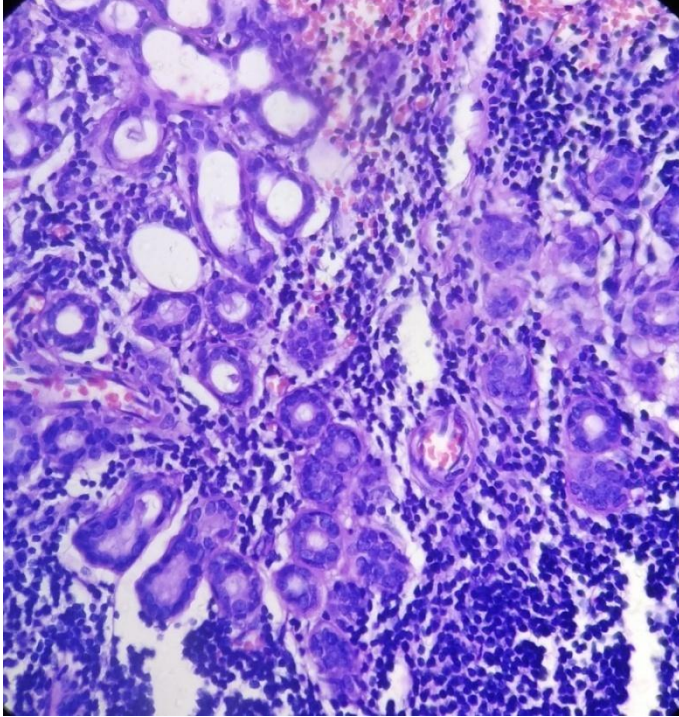
Type of Tumour	Total Cases	Average Age	Sex		Site			
			Female	Male	Parotid	Sub Mandibular	Sub Lingual	Minor
Adenocystic Carcinoma	2	52.50±3.53	1	1	0	0	2	0
Adenocarcinoma	2	48.00±32.52	1	1	0	0	2	0
Mucoepidermoid Ca	3	45.00±5.00	2	1	1	0	2	0
Carcinoma Ex Pleomorphic	1	58.00±0.00	0	1	0	0	1	0



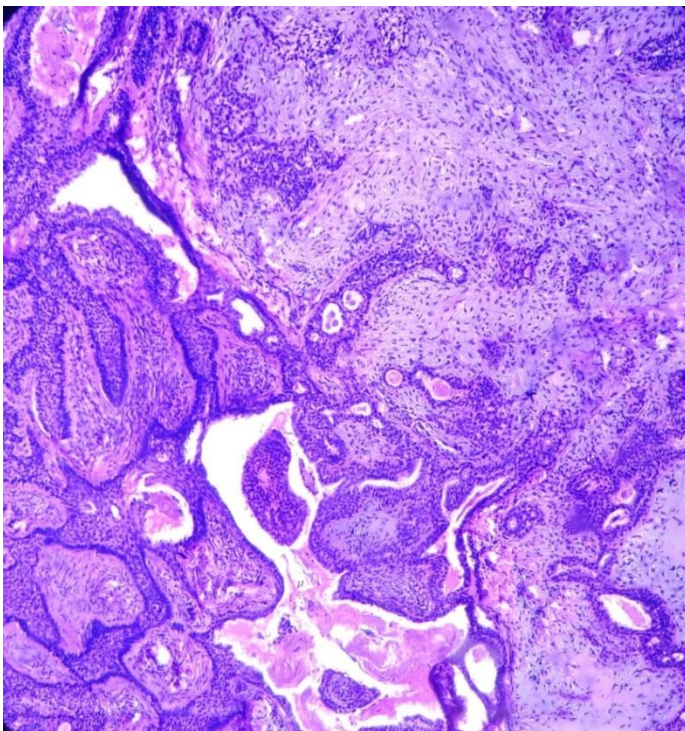
10X : Adenoid Cystic Carcinoma – Cribriform pattern predominantly these cribriform spaces contain light basophilic mucin. These spaces are pseudocyst Surrounded by basaloid (modified myoepithelial cells)



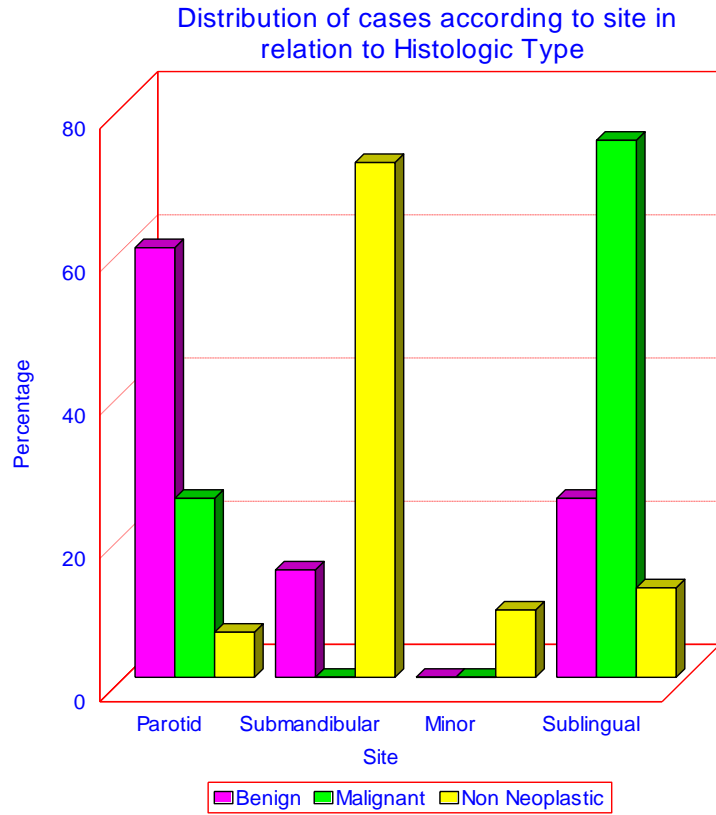
10X : Mucoepidermoid Carcinoma – Sheet of tumor cell lying in sclerotic stroma along with necrosis



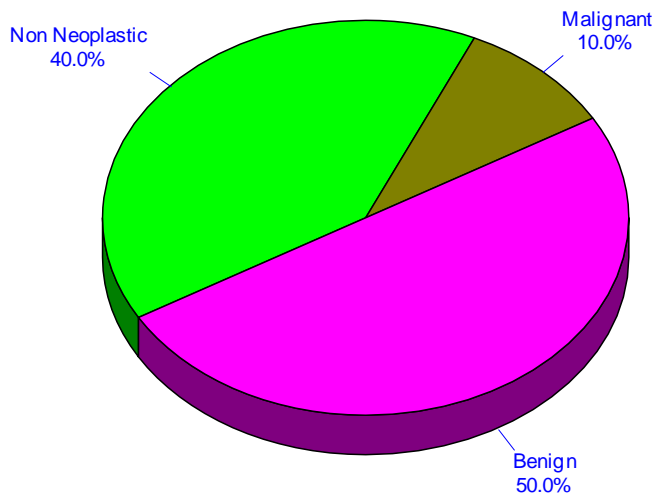
40X : Chronic Non Specific Sialadenitis – Showing increase vascularity and lymphocytic infiltrate in between normal salivary gland



10X : Pleomorphic Salivary Adenoma Anastomosed tubules, cord of dual cell type apparently “melt” into myxoid stroma



Shows percentage of various tumours according to WHO Classification



DISCUSSION

INCIDENCE OF SALIVARY GLAND LESIONS IN BIKANER ZONE

Our study indicated that neoplastic lesions were more common than non neoplastic lesions. In our study, out of 80 cases, 32(40%) cases were non neoplastic lesions, and mean age of non neoplastic lesions was 37.34 ± 18.05 , male to female ratio were 1.47:1 and according to site, submandibular gland was most common site of non neoplastic lesions (23 cases), followed by sublingual (4 cases) and minor salivary gland (3 cases) and least commonly involved parotid gland (2 cases).

PLEOMORPHIC ADENOMA

In our study pleomorphic adenoma was the most common type of benign salivary gland neoplasm. According to our study, male to female ratio was 3.57:1. Incidence of pleomorphic adenoma is more common in males consistent with de-Oliveira et al (1:1.6). Reynolds et al, Panda et al and Sengupta et al, Eneroth et al, Lowrence et al and Pogrel et al.

Age

In present study, mean age of pleomorphic adenoma was 31.75 ± 9.74 years. Which is consistent with Sengupta et al, Vuhahula et al and Musanai et al.

Location

In present study, most common site for pleomorphic adenoma was parotid gland. (53%), followed by submandibular gland (15.61%) which is consistent with Sengupta et al and Ansari et al.

Clauser et al, Ladeinde et al, Gpotolorum et al, study show that the most common site of pleomorphic adenoma is minor salivary gland (palate), which is in contrast with our study.

WARTHIN'S TUMOUR

In our study, Warthin's tumour was second most common benign neoplasm after pleomorphic adenoma. It accounts for 5(10.4%) cases of benign neoplasm which is consistent with the study done by Sengupta et al and Gupta et al.

Age and Sex Incidence

Warthin's tumour was more common in male as compared to female. M:F ratio was 1:0.67. Our study is consistent with Tian et al.

De Oliveira et al, study shows that Warthin's tumor is more common in female, which is in constant to our study.

Average age of Warthin's tumour was 45.40 ± 20.51 years and most common site was parotid gland which is consistent with Eneroth.

INCIDENCE OF MALIGNANT NEOPLASM IN BIKANER ZONE

Incidence of malignant neoplasm constitute of 28% of all neoplasm.

INCIDENCE OF VARIOUS MALIGNANT NEOPLASM WITH AGE AND SEX

According to our study, the most common malignant epithelial neoplasm was mucoepidermoid carcinoma (n=3; 37.5%).

Second most common neoplasm was adenoid cystic carcinoma.

Followed by adenocarcinoma 2(25%) cases, and 1 case of carcinoma Ex pleomorphic adenoma.

Mean age for mucoepidermoid carcinoma was 45.00 ± 5.00 and for adenoid cystic carcinoma was 52.50 ± 3.54 , these finding are consistent with other studies like Ansari et al and Tian et al.

According to our study malignant neoplasm was rare in children which is consistent with Balghiti et al. Where Thariat et al in their study says that 50% of malignant salivary gland neoplasm were in children. According to our study, mean age was 51.5 years.

In our study male and female were equally affected by malignant neoplasm. M:F ratio was 1:1. Our study is consistent with Panda et al, Gerughty et al and Thomas et al.

However one study shows female predominance i.e. Francis et al.

SUMMARY AND CONCLUSION

This is a prospective histopathological study on salivary gland lesion, carried out in the Department of Pathology, S.P. Medical College and Associated Group of Hospitals, Bikaner over a period of 3 years.

- Lobulectomy, biopsies as well as complete excised salivary gland received in department during this period were included for the study.
- The number of specimen included for the study were 80.
- Lesion were further divided into neoplastic and non neoplastic lesion. Non neoplastic lesions were divided into CNSS, lymphoepithelial cyst, myxoid cyst and TB, while neoplastic tumours were divided into two groups i.e. Benign and Malignant.

BENIGN NEOPLASM

- In Bikaner zone, benign neoplasm is predominant than malignant.
- Out of total 80 cases, 48(60%) cases were benign neoplasm.
- 24(60%) cases benign tumor occur in the parotid gland, 6(15%) cases in the submandibular gland and 10(25%) cases in the sublingual gland (palate).
- Out of 40 cases 11(27.5%) cases were in female and 29(72.5%) cases were in male. Female:Male ratio was 1:2.7.
- Out of total 40 cases, maximum number of patients 25(62.5%) cases were found between age group 21-40 years. Out of these 25 patients, 13(32.5%) cases were in 21-30 and 12(30%) were in 31-40 years age group.
- In 0-10 years age group, no case was found
- In 11-20 years age group, 5(12.5%) cases were found
- In >60 years 2(5%) cases were found

Pleomorphic Adenoma

- Out of total, 40 benign Neoplasm 32(80%) cases were pleomorphic adenoma.

- Out of these, 17(53.1%) cases of parotid gland, 5(15.6%) cases of submandibular gland and 10(31.3%) cases of sublingual gland (Palate).
- Out of total 32 cases 25(77.4%) cases were present in male and 7(22.6%) cases were in female.
- In present study, Female to Male ratio was 3.5:1.
- Average age for pleomorphic adenoma was 31.75 ± 9.74 .
- Most of cases (n=30) occurred between 11 to 40 years.

Warthin's Tumor

- Out of total 40 benign salivary gland tumors, 5(12.5%) cases were Warthin's tumour.
- Out of 5 patients, 2(40%) cases were female and 3(60%) cases were male.
- Male to female ratio was 1.3:1.
- Average age was 45.4 ± 20.51 years.
- Out of 5 cases, all were present in parotid gland.

MALIGNANT EPITHELIAL NEOPLASM

- In Bikaner zone, incidence of malignant neoplasm is 10% (n=8).
- In malignant neoplasm, mucoepidermoid carcinoma constitute 3(37.5%) cases, adenoid cystic carcinoma were 2(25%) cases, and adenocarcinoma 2(25%) cases and carcinoma ex pleomorphic adenoma 1(12.5%) cases.
- Out of 8 malignant neoplasm, 2(25%) cases were present in parotid gland and 6(75%) cases were present in sublingual gland.
- Incidence of malignant salivary gland neoplasm is equal in males and females (4 patients each).
- Male to female ratio was 1:1.
- No case was found between 0-20 years age group.
- 1(12.5%) case was in 21-30 years age group, 1(12.5%) was in 31-40 years age group. In 41-50 years, 3(37.5%) cases and in 51-60 years, 2(25%) and in >60 years, 1(12.5%) cases were found.
- Mean age for adenoid cystic carcinoma was 52.50 ± 3.53 years while for mucoepidermoid carcinoma it was 45.00 ± 5.00 and for adeno-carcinoma 48.00 ± 32.53 years.
- Follow up of the patients is suggested to know the prognosis and further evaluations.

BIBLIOGRAPHY

1. Andreola S, Sirizzatti G. Mucoepidermoid carcinoma of salivary glands : Clinicopathological review of 108 patients treated at the National Cancer Institute of Milan Ann surg. Oncol 2002; 9(7) : 688-95.
2. Ansari MH. Salivary gland tumors in an Iranian population: a retrospective study of 130 cases. J Oral Maxillofac Surg 2007; 65:2187-94.
3. Belghiti H, Znati K, Harmouch T, Amarti A, Zaki Z, El Alami MN. Mucoepidermoid carcinoma of the parotid gland in young children. Rev Stomatol Chir Maxillofac. 2011;112(2):110-2.
4. Bentz BG, Hughes CA, Lüdemann JP, Maddalozzo J. Masses of the salivary gland region in children. Arch Otolaryngol Head Neck Surg. 2000; 126(12) : 1435-9.
5. Bentz BG, Hughes CA, Lüdemann JP, Maddalozzo J. Masses of the salivary gland region in children. Arch Otolaryngol Head Neck Surg. 2000; 126(12) : 1435-9.

6. Brandwein MS, Ferlito A, Bradley PJ. Diagnosis and classification of salivary neoplasm, pathologic challenges and relevance of clinical outcome. *Acta Otolaryngol* 2002; 122(7) : 758-64.
7. Chong GC, Beahrs OH, Woolner LB. Surgical management of acinic cell carcinoma of the parotid gland.
8. Clauser L, Mandrioli S, Dalleria V, Sarti E, Galiè M, Cavazzini L. Pleomorphic adenoma of the palate. *J Craniofac Surg*. 2004; 15(6) : 1026-9.
9. de Oliveira FA, Duarte EC, Taveira CT, Máximo AA, de Aquino EC et al. Salivary gland tumor: a review of 599 cases in a Brazilian population. *Head Neck Pathol*. 2009; 3(4) : 271-5.
10. Eneroth CM. Salivary gland tumour in the parotid gland, Submandibular gland and the palate region. *Cancer* 1971; 27 : 1415.
11. Francis ES. Systemic evaluation of the WHO classification of salivary gland tumours. *Am J Clin Pathol* 1977; 67 : 272.
12. Gbotolorun OM, Arotiba GT, Effiom OA, Omitola OG. Minor salivary gland tumours in a Nigerian hospital: a retrospective review of 146 cases. *Odontostomatol Trop*. 2008; 31(123) : 17-23.
13. Gerughty RM, Scofield HH, Captain DC, Brown FM, Hennigar GR. Malignant mixed tumours of salivary gland origin. *Cancer* 1969; 24 : 47.
14. Good RK, Auclair PL, Eillis GL. Mucoepidermoid carcinoma of major salivary gland: *Cancer* 1998; 82 (7) : 1217-24.
15. Gooden E, Witterick IJ, Hacker D. Parotid gland tumors in 255 consecutive patients: *J Otolaryngol* 2002; 31(6) : 351-4.
16. Gupta SK, Sen Gupta P, Sarkar SK. Primary tumor of salivary glands. *JLMA* 1975; 65 : 277.
17. Jaber MA. Intraoral minor salivary gland tumors: a review of 75 cases in a Libyan population. *Int J Oral Maxillofac Surg*. 2006; 35(2) : 150-4.
18. Kristen WH. Quoted from Evans and Cruickshank. *Epithelial tumours of the salivary glands* 1967.
19. Ladeinde AL, Adeyemo WL, Ogunlewe MO, Ajayi OF, Omitola OG. Salivary gland tumours: a 15-year review at the Dental Centre Lagos University Teaching Hospital. *Afr J Med Med Sci*. 2007; 36(4) : 299-304.
20. Lawrence SE, David SJ, Harvery WB. Adenocystic carcinoma of head & neck. *Cancer* 1972; 29 : 1160.
21. Mendenhall WM, Werning JW, Pfister DG. *Treatment of head and neck cancer*. 2011; 729-80.
22. Musani MA, Sohail Z, Zafar S, Malik S. Morphological pattern of parotid gland tumours. *J Coll Physicians Surg Pak*. 2008; 18(5):274-7.
23. Pogrel MA. Tumours of salivary glands. *Br J Oral Surg* 1979; 17 : 47.
24. Rosai & Ackerman's *Surgical Pathology* 9th edition: 873.
25. Seifert G, Sobin LH. *Histological typing of salivary gland tumors*: 2nd ed. Berlin Germany : Springer-Verlag, 1991.
26. Sen Gupta SK, Banerjee AK, Datta BN. Primary tumours of salivary glands. An analysis of 11 cases. *Ind J Pathol Bact* 1973; 16 : 32.
27. Speight PM, Barrett AW. Salivary gland tumours, *Oral Dis* 2002; 8(5) : 229-40.

28. Thariat J, Vedrine PO, Orbach D, Marcy PY, Badoual C, et al. Salivary gland tumors in children. *Bull Cancer*. 2011; 98(7) : 847-55.
29. Thomas KM, Hutt MSR, Burgstein J. Salivary gland tumor in malani. *Cancer* 1980; 46 : 2358.