



CHIKUNGUNYA FEVER AS A CAUSE OF NEPHROTIC SYNDROME

Dr. Smita Nath, Dr. Pinkesh Parmar, Dr. Karan Chabra, Prof DR. S. Kumar, Prof Dr. Sandeep Garg

Maulana Azad Medical college Medical college and Lok Nayak Hospital, New Delhi, INDIA

ABSTRACT

Chikungunya fever is a viral disease caused by chikungunya virus(CHIKV), and transmitted by the bite of infected *Aedes aegypti* mosquitoes. Chikungunya virus (CHIKV) is a member of the genus Alphavirus, in the family *Togaviridae* and was first isolated from Tanzania in 1953. The CHIKV was first identified in India in 1963, in kolkatta. The outbreaks seemed to decline in the late 20th century, with no case reports after 1973. However since its resurgence in 2006 in various parts of the country, this tenacious epidemic has manifested itself in myriad ways especially in the 2016 outbreak in Delhi. Along with typical signs and symptoms many atypical manifestation of the chikungunya fever was seen during the current upsurge of disease. We present the case of an 18-year-old girl who presented with nephrotic syndrome in course of chikungunya fever.

KEY WORDS: chikungunya fever, atypical manifestations, nephrotic syndrome

INTRODUCTION

Chikungunya fever is a viral disease transmitted by the bite of infected *Aedes aegypti* mosquitoes. Chikungunya virus (CHIKV) is a member of the genus Alphavirus, in the family *Togaviridae* and was first isolated from the blood of a febrile patient in Tanzania in 1953². Since identification, CHIKV has caused numerous epidemics in west, central and southern Africa and many areas of Asia^{1,3}. In 'Swahili' language, Chikungunya means that which contorts or illness of the bended walker referring to the contorted (or stooped) posture of afflicted patients due to arthritis, which is common feature of the disease³. In the Indian sub-continent, since its first isolation in Calcutta during 1963, there have been several reports of Chikungunya virus infection in different parts of India viz: Kolkata, Pondicherry and Chennai in Tamil Nadu, Rajamundry, Vishakapatnam and Kakinada in Andhra Pradesh, Sagar and Nagpur^{4,5}. The last outbreak of Chikungunya infection in 20th century occurred in India during 1973. After a quiescence of 2-3 decades there was resurgence of chikungunya fever during 2006 in several parts of India. The re-emergence of Chikungunya may be due to a variety of social, environmental, behavioural and biological factors, of which lack of herd immunity may be a major contributing factor^{1,4,5}.

CHIK virus causes an acute febrile illness with an incubation period of 3-7 days (can be 2-12 days,). Viremia persists for up to 5 days from the onset of symptoms. Fever and arthralgia are the hallmarks of Chikungunya fever apart from which myalgia, headache, and diffuse maculopapular rash are often associated. Other clinical symptoms such as diarrhoea, vomiting, persistent arthralgia, and on rare occasions bleeding, have also been described.⁶ Association of Chikungunya fever with hepatitis, meningitis, encephalitis, myocarditis and arrhythmias have been reported^{1,5}. In one of the largest outbreaks of chikungunya in Reunion Islands during 2005 - 2006 a total of 610 atypical cases were

reported. The definition of atypical manifestation being, 'A patient with laboratory-confirmed Chikungunya virus infection with symptoms other than fever and arthralgia'⁷. Various renal involvement have also been described in chikungunya fever including proteinuria, azotaemia, oliguria and nephritic syndrome. We report the case of an 18-year-old patient with laboratory confirmed chikungunya virus infection with nephrotic syndrome

CASE REPORT

An 18-year-old girl with chief complaints of abdominal distension for 15 days following short febrile illness of 5 days' duration. These symptoms were associated with polyarthralgia and headache. However there was no history of hematuria, oliguria, mucosal bleeding, jaundice, rash, weight loss, arthritis. On clinical examination patient had no pallor, jaundice, lymphadenopathy, rash, cyanosis, clubbing and her JVP was not raised. She had B/L pitting pedal oedema and examination of abdomen revealed presence of ascites. Haematological investigations showed a Hb of 10.2gm%, TLC of 5200/dl, platelet count of 2.56 lakh. Her kidney functions were deranged with blood urea of 74gm/dl and serum creatinine of 2.2 gm/dl. Her urine routine microscopic examination showed 3+ albumin with nil RBC. Her total serum protein was 3.0gm/dl with albumin of 1.0gm/dl. Her serum cholesterol levels were 600mg/dl and triglycerides were 660mg/dl. Liver function test were normal. Analysis of ascitic fluid came up with a report of 10 cells with a sugar of 52mg and protein of 0.4mg. A24-hour urine protein revealed a proteinuria of 6gm/24hrs. Urine also showed inactive sediments with significant proteinuria. Based on above findings ANA and ANCA serology was sent which came out to be negative. Her HIV, Hepatitis B and Hepatitis C serology was negative. Since in this case nephrotic range proteinuria was preceded by fever and polyarthralgia serological markers for dengue, malaria and chikungunya were sent. Her anti-chikungunya IgM antibody came out to be positive and dengue and malaria was negative. Ultrasound of abdomen and pelvis was normal. A provisional diagnosis of chikungunya fever with nephrotic syndrome was made and patient was taken up for kidney biopsy. The renal biopsy picture was consistent with minimal change disease (figure 1).

Following the treatment protocol patient was started on oral prednisolone dose of 1mg/kg body weight along with ACE inhibitors. When patient was reassessed after four weeks her 24 hour urine protein decreased to a level less than 200mg/dl and serum creatinine became 0.9mg/dl and patient had shown a consistent improvement.

DISCUSSION

Chikungunya fever is characterized as a mild febrile disease. The main clinical symptoms mentioned are fever, incapacitating arthralgia, myalgia, headache, and diffuse maculopapular rash^{1,6}. Other clinical symptoms are diarrhoea, vomiting, persistent arthralgia, and bleeding diathesis^{1,6}. Only a few case reports have been published suggesting that Chikungunya fever can be exceptionally associated with hepatitis, meningitis, Encephalitis, myocarditis and arrhythmias⁶.

Although considered a mild self limiting febrile illness, the capricious nature of chikungunya infection is evident from its wide spectrum of clinical manifestation as well as unpredictable outbreak patterns. After lying quiescent for almost three decades, the disease has resurfaced in various parts of world in a mercurial pattern^{2,3,4}. One of the most explosive outbreaks was in the reunion islands between 2005-2006⁷. During this outbreak a total of 610 cases with atypical presentation were identified which included arrhythmias, myocarditis, meningoencephalitis, GBS, acute liver failure and acute kidney injury⁷.

As far as the renal manifestations are concerned AKI is most common, although cases of nephritic syndrome have been reported^{7,8}. Our case brings out another novel manifestation in

form of nephrotic syndrome. We have extensively worked up this patient for some other known cause of nephrotic syndrome. The association of nephrotic range proteinuria along with the positive serology for chikungunya in absence of other known causes suggests its association with it. However further large data based studies and continuous surveillance is required before it can be labelled as a cause of Nephrotic syndrome

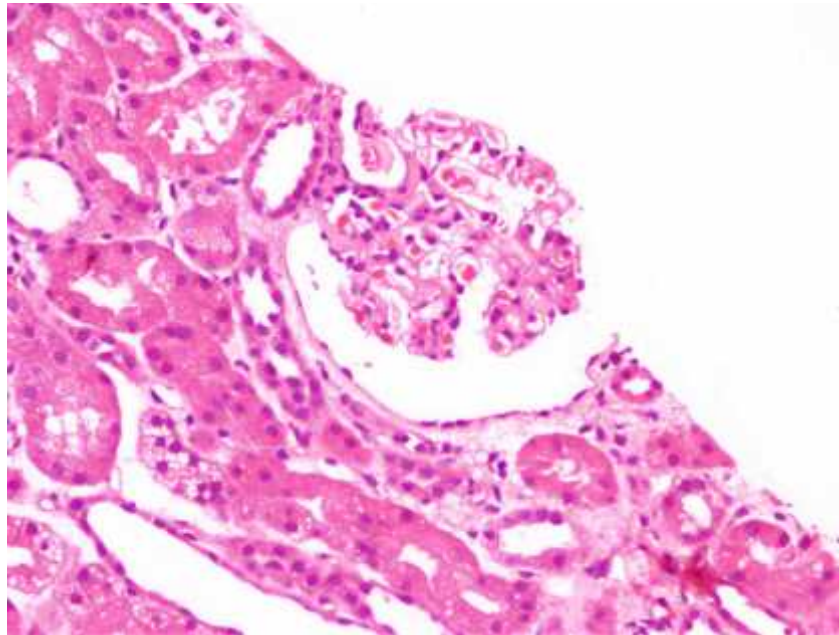


FIG 1: Kidney biopsy showing mild increase in mesangial matrix and cellularity without basement membrane thickening or segmental sclerosis on silver methenamine stain. Immunoflorescence showed no significant immune deposits. Findings were consistent with Minimal change disease.

REFERENCES

1. National guidelines for clinical management of chikungunya 2016: Directorate of national vector borne disease control programme
2. Pialoux G, et al. Chikungunya, an epidemic arbovirosis. *Lancet Infect Diseases* 2007; 7: 319–327.
3. Charrel RN, de Lamballerie X, Raoult D. Chikungunya outbreaks – the globalization of vectorbornedisease. *New England Journal of Medicine* 2007; 356: 769–771
4. ChandrakantLahariya& S.K. Pradhan Emergence of Chikungunya virus in Indian subcontinent after 32 years: a review *J Vector Borne Dis* 43, December 2006, 43 (4): 151-60
5. Chhabra M, Mittal V, Bhattacharya D, Rana U, Lal S. Chikungunya fever: a re-emerging viral infection. *Indian J Med Microbiol.* 2008 Jan-Mar; 26 (1): 5-12.
6. Mohan A. Chikungunya fever: clinical manifestations & management. *Indian Journal of Medical Research.* 2006 Nov; 124(5) : 471-4.
7. A. Economopoulou, M. Dominguez, B. Helynck, D. Sissoko, O. Wichmann, P. Quenel, P. Germonneauand I. Quatresous. Atypical Chikungunya virus infections: clinical manifestations, mortality and risk factors for severe disease during the2005–2006 outbreak on Re´union. *Epidemiol. Infect.* (2009), 137, 534–541
8. B.S Solanki, S.C Acharya, P.Maheshwari. Chikungunya disease with nephritic syndrome: *Int Journal of clinical practice*, nov 2007, 61(11) 1941